



PATIENT

Mya Gale

SPECIES

Canine

BREED

Maltese Mix

SEX

Male Neutered

AGE

8 years

WEIGHT

10.9lbs

INTERPRETED BY

Maggie Machen
Lamy, DVM
DACVIM (Cardiology)

IMAGING PERFORMED BY

Pamela Harrigan,
RDCS

HOSPITAL NAME

Mass Veterinary Services

REFERRING VET

Dr. Masloski

INVOICE

25168

DATE

7/6/22

PRESENTING CLINICAL SIGNS

History: Mya is referred to evaluate a heart murmur noted in March. She is doing well at home with a good appetite and relatively normal activity. On exam today: NSR, grade III/VI murmur with PMI left apical area, PSS, lung fields clear. BP: 160mmHg x 5. Currently, no medications. *Sedated with propofol for study.

ECHOCARDIOGRAM FINDINGS

2D, m-mode, color flow and Doppler imaging is available.

Left ventricle: The LV diameter is normal with adequate myocardial function. LV wall thicknesses are normal.

Left atrium: The left atrium is mildly dilated.

Mitral valve: The mitral valve is mildly thickened with mild prolapse into the left atrial lumen. Mild to moderate eccentric mitral regurgitation with a normal velocity.

Aortic valve/aorta: The aortic valve is normal in morphology and mobility. Normal aortic outflow velocity; laminar flow. No aortic insufficiency.

Right ventricle: Mild RV enlargement.

Right atrium: Mild RA enlargement.

Tricuspid valve: The tricuspid valve appears thickened with marked septal prolapse and moderate double jet of tricuspid regurgitation. Velocity consistent with early pulmonary hypertension.

Pulmonic valve/pulmonary artery: The pulmonic valve is normal in morphology and mobility. No pulmonic insufficiency. Normal RVOT velocity; laminar flow. Mild MPA and branch dilation.

Pericardium/other: No pericardial or pleural effusion noted. No obvious cardiac masses.

Heart rhythm: ECG reveals a sinus rhythm with an average HR of 140bpm.

2-Dimensional Measurements

Ao diam (cm)	1.3
LA diam (cm)	1.8
LA:Ao (Swe)	1.4
IVS thickness (cm)	0.7
LVID diastole (cm)	1.8
PW thickness (cm)	0.8
LVID systole (cm)	1.2
FS (%)	33

Doppler Measurements

PV Vmax (m/s)	0.76
AoV Vmax (m/s)	0.95
MR Vmax (m/s)	4.5
TR Vmax (m/s)	2.8
TR PG (mmHg)	32

INTERPRETATION OF THE FINDINGS

The cause of the murmur is chronic degenerative valve disease causing mild to moderate mitral and moderate tricuspid regurgitation. Early PAH is noted with mild right heart and MPA dilation. This is of unknown significance in an asymptomatic dog; however, follow up is advised. Lack of significant left atrial enlargement indicates the current risk for complication is low. No concurrent issues such as systolic dysfunction or pulmonary hypertension are noted in this study.

Assessment of progression in the future will help predict long term prognosis, which is highly variable at this stage (B1).



PATIENT

Mya Gale

SPECIES

Canine

BREED

Maltese Mix

SEX

Male Neutered

AGE

8 years

WEIGHT

10.9lbs

INTERPRETED BY

Maggie Machen
Lamy, DVM
DACVIM (Cardiology)

IMAGING PERFORMED BY

Pamela Harrigan,
RDCS

HOSPITAL NAME

Mass Veterinary
Services

REFERRING VET

Dr. Masloski

INVOICE

25168

DATE

7/6/22

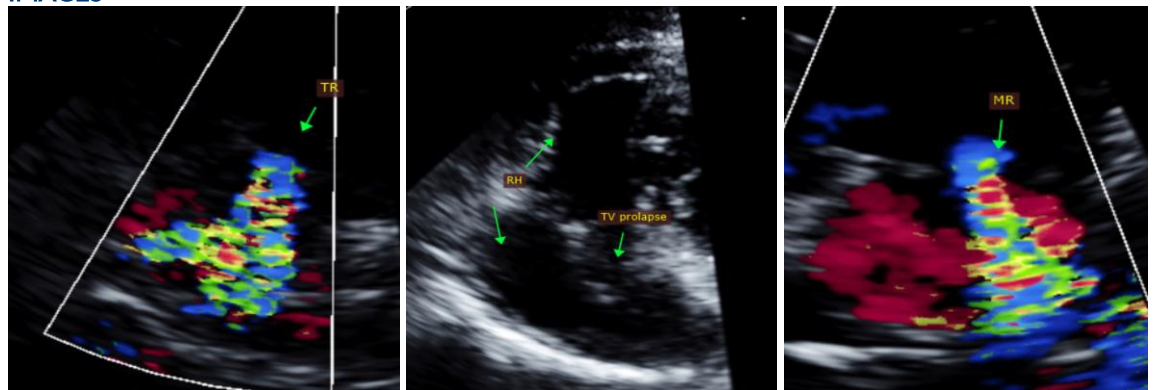
RECOMMENDATIONS

- In a dog without significant left atrial enlargement, no cardiac medications are clearly indicated.
- Omega fatty acid supplementation and mild salt restriction may be of some long-term benefit.
- Anesthetic risk is considered mild if needed. Cardiac protective drug choices are recommended. Pre-oxygenate for 5-10 minutes prior to induction. Monitor for arrhythmias, hypotension, and hypoxia both intra and post-operatively and intervene as necessary. Mild IV fluid restriction is recommended to avoid fluid overload.
- Monitor for development of a cough, labored breathing, exercise intolerance or collapse episodes.

PLAN

- Recommend conservative monitoring with a recheck echocardiogram in 6 months, sooner if any development of clinical signs.

IMAGES



The information and recommendations provided are based on the images presented by the referring veterinarian. No evaluation can be communicated regarding pathology that was not visible in the image/video clips provided.

Thank you for this referral. This report was generated using transcription software, and minor dictation errors may be present. If the clinical or image interpretation does not parallel your findings or if I can be of any further assistance, please contact me.

Maggie Machen Lamy, DVM
Diplomate of the American College of Veterinary Internal Medicine (Cardiology)
info@sonopath.com

Echocardiogram performed by:

Pamela Harrigan, RDCS
Pet Animal Ultrasound Service (4paus.com)